



American Journal of Surgical Research and Reviews (ISSN:2637-5087)



The Feasibility of Early Closure of Defunctioning Loop Ileostomy after Low Anterior Resection for Rectal Cancer

Ahmed S. Elgammal^{1*}, Ahmed Gaber¹, Ahmed Fawzy¹

¹General Surgery Department, Faculty of Medicine, Menoufia University, Egypt.

ABSTRACT

Background: The advantages of defunctioning loop ileostomy in some cases of rectal carcinoma is not questionable, but many patients experience serious stoma related complications and impaired quality of life. Early closure of the defunctioning ileostomy could mitigate these problem.

Methods: This is a controlled randomized study done on 100 patients suffering of rectal cancer who had low anterior resection of the rectum and covering ileostomy at Menofiya University Hospital between April 2016 to august 2019. The patients were randomly divided (by closed envelope method) in two equal groups, Group A (Early group) and Group B (Late group).

Results: As regards the pre-closure ileostomy complications: skin infection and maceration occurred in 4 pts. In early group and in 15 pts.in late group while dehydration and electrolyte imbalance occurred in 3 pts. In early group and in11 pts. In the late one, with both complications were significantly higher in late group (P value; 0.009 and 0,04 respectively). The health related quality of life was found to be higher in early group at 2 and 6 months than that in late group, but this did not yet reach significant difference, and at 12 month, the results were almost the same.

Conclusion: Early ileostomy closure is safe, and not associated with higher complication rates in patients with an uncomplicated postoperative course and radiologically verified intact distal loopogram study.

Keywords: Early closure; Rectal resection; Rectal cancer; Loop ileostomy

*Correspondence to Author:

Dr. Ahmed Sabry Elgammal
Department of General Surgery,
Faculty of Medicine, Menoufia
University, Egypt.

How to cite this article:

Ahmed S. Elgammal, Ahmed Gaber, Ahmed Fawzy. The Feasibility of Early Closure of Defunctioning Loop Ileostomy after Low Anterior Resection for Rectal Cancer. American Journal of Surgical Research and Reviews, 2021; 4:19.

 eSciPub
eSciPub LLC, Houston, TX USA.
Website: <https://escipub.com/>

Introduction

Colorectal cancer is the third most commonly diagnosed malignancy worldwide and the third leading cause of cancer death in the United States.

Rectal cancer occurred mainly in elderly people [1].

In Egypt, nowadays, according to NCI database, there is a shift towards higher incidence in younger population than rest of the world [2].

Recent advances in the management of low rectal cancer (as neoadjuvant chemoradiotherapy, introduction of stapling devices and implementation of laparoscopic, TaTME and robotic techniques) increase the number of patients treated by sphincter – saving procedures [3].

Despite many improvements in the quality of rectal cancer surgery, anastomotic leak rates remain between 10% and 15%. The adverse effect of such leaks is fatal in some cases [4,5].

Intestinal anastomoses are frequently created in patients undergoing surgery for rectal cancer with simultaneous construction of a covering ileostomy. This is done to limit the consequences of anastomotic leakage [6].

A recent Cochrane review concluded that a covering ileostomy is associated with fewer anastomotic leakages, and a decrease in the need for urgent reoperation has also been reported [7].

In spite of this great advantage, it affects the patient quality of life and has its own morbidity as skin complications, fluid and electrolyte disturbance and parastomal hernia [5].

Covering ileostomy should be used in certain conditions that may affect the integrity of the intestinal anastomosis.

Strong indications are: anastomotic imperfections, anastomosis under tension, previous pelvic irradiation, ultralow anastomosis, patients over 70 years, and significant patient co-morbidities [8]. The time of ileostomy closure is still debatable and differs from one institution to the others.

Early closure of the temporary loop ileostomy might reduce both stoma-related morbidity and

patient discomfort but it has its own side effects of technical difficulties and wound infection [9].

This study reports the results of a randomized trial of early versus late closure of the covering ileostomy after rectal resection for cases of rectal cancer.

Patients and Methods

This is a controlled randomized study done on 100 patients suffering of rectal cancer who had low anterior resection of the rectum and covering ileostomy at Menoufia university hospital between April 2016 to August 2019.

The study was approved by the ethics committee of the hospital and was registered on the trial register (numb. Written informed consent was obtained from all patients.

Inclusion criteria:

All adult patients (+18 years) treated in our hospital with curative intent from rectal cancer by low or ultralow anterior resection of the rectum with creation of temporary defunctioning ileostomy.

The patients were randomly divided (by closed envelope method) in two equal groups, Group A (Early group) and Group B (Late group).

In the early group, the stoma will be closed after two weeks of the index operation while in the late group, it will be closed after two months.

All demographic data, oncological data (regarding the tumor type, site, grade, stage and neoadjuvant therapy) and surgical details of index operation (type of resection, time, complications) were recorded.

After the rectal resection, all patients were followed up closely as regards, vital signs, regaining of bowel movement, nutrition and early postoperative complications.

At the 14th day (for early group), after creation of the stoma, fit patients eligible for closure will undergo a CT of the rectum with a water-soluble contrast medium to visualise the anastomosis and possible leakage.

Closure of the ileostomy was performed under general anaesthesia with a peristomal skin incision, mobilization and a hand-sewn anastomosis.

The fascia was closed and the skin could be left

partially open, or was closed primarily.

In the late group, a second antegrade Contrast CT radiograph was performed via the stoma after 2 months, just before stoma closure, to assess the integrity of the anastomosis.

Outcomes

All patients were followed up for 12 months after the rectal resection. The primary endpoints were morbidity and mortality rate while the secondary endpoint is the quality of life for the same time by using The Gastrointestinal Quality of Life Index^[10].

Statistical Analysis

The collected data were organized, tabulated and statistically analysed using SPSS software

(Statistical Package for the Social Sciences, version 21, SPSS Inc. USA). Data were described using mean and standard deviation (SD) and frequencies according to the type of the data (quantative or categorical respectively). Categorical variables were compared using chisquare analysis or Fisher exact test. In all tests, data with a P < 0.05 were considered statistically significant. We used one way Anova test to compare between means of categorical and numerical data. The area under the ROC curve for each scale was used to calculate false negative rate, false predictive value of the studied models.

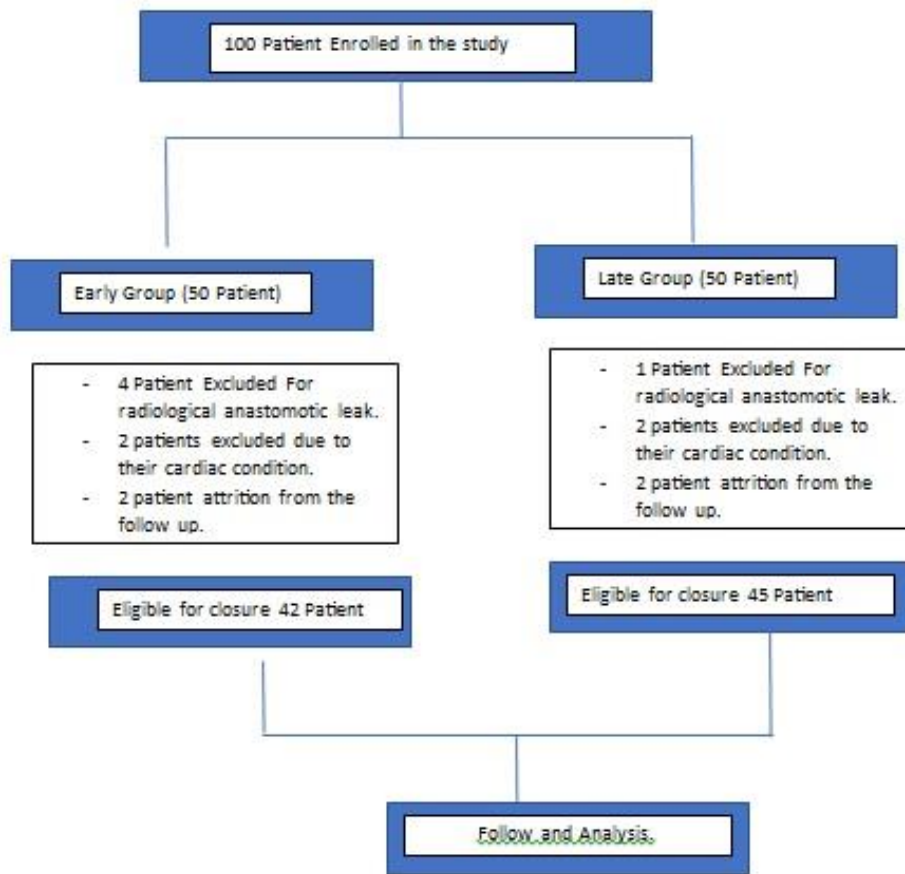


Fig 1: diagram of the study design

Results

100 patients had enrolled in this study and randomly divided in two equal groups. 13 patients excluded from the study {8 from group (1) and 5 from group (2)} due to manifest anastomotic leak,unstable health condition or loss of follow up. **(Fig. 1).**

Both groups are homogeneous as regards patient demographics and tumor characteristics. The mean age in both group is around 50 years (51, 8 and 49,6 respectively), most of them were male (54/87,62%) and about two thirds of them had one or more comorbidities. **(Table 1).** Most of the tumors resected in this study were

located at the lower third of the rectum (52,9%, 46/87), (48,3%, 42/87) stage 3 and (82,8%, 72/87) were down staged by neoadjuvant therapy. **(Table 2).**

Laparoscopic rectal resection was done in (21/87, 24,1%), and colo-rectal anastomosis was accomplished in the majority of cases (77/87, 88,5%). **(Table 3).**

As regards the pre-closure ileostomy complications: skin infection and maceration occurred in 4 pts. In early group and in 15 pts. in late group while dehydration and electrolyte imbalance occurred in 3 pts. In early group and in 11 pts. In the late one, with both complications were significantly higher in late group (P value; 0.009 and 0,04 respectively). **(table 4)**

The mean operative time was slightly longer in

early group (68 min.vs 59min.) with no significant statistical difference between both groups. **(Table 6).**

After closure, surgical site infection occurred in 9 patients (7 in early group and 2 in late one) and was managed successfully by simple local drainage and antibiotics, while entero-cutaneous fistula developed in 3 patients (2 was closed spontaneously by conservative treatment and one case, in early group, laparotomy was needed for intraperitoneal infection). (table 5)

The health related quality of life was found to be higher in early group at 2 and 6 months than that in late group, but this did not yet reach significant difference, and at 12 month, the results were almost the same.

Table 1: Demographics

	Type		Total	P value
	Early Group	Late Group		
Age Range Mean	32 - 69 M 51.8+/- 10.7	29 - 65 49.6+/- 11.4	-	1.0
Male Female	28 14	26 19	54 33	0.508
Comorbidities				
No	17	14	31	0.381
Yes	25	31	56	

Table 2: Tumor Characterization

	Type		Total	P Value
	Early Group	Late Group		
Site				
Upper	6	4	10	0.559
Middle	16	15	31	
Lower	20	26	46	
Staging				
I	2	3	5	0.681
II	20	17	37	
III	18	24	42	
IV	2	1	3	
Neoadjuvant				
No	8	7	15	0.779
Yes	34	38	72	

Table 3: Type of index surgery

	Type		Total
	Early Group	Late Group	
Type_surgery			
Open	34	32	66
Lap	8	13	21
Type_Anastmosis			
Colo-rectal	37	40	77
Colo-Anal	5	5	10

Table 4: Stoma-related Complication

	Early Group	Late Group	Total	P Value	
Skin_infection	No	38	30	68	0.009
	Yes	4	15	19	
Stenosis	No	41	45	86	0.483
	Yes	1	0	1	
Prolapse	No	42	44	86	0.517
	Yes	0	1	1	
Retraction	No	41	43	84	0.526
	Yes	1	2	3	
Parastomal_hernia	No	42	42	84	0.134
	Yes	0	3	3	
Dehrdration	No	39	34	73	0.04
	Yes	3	11	14	

Table 5: post-Closure Complication

	Type		Total	P value	
	Early Group	Late Group			
Skin infection	No	35	43	78	0.083
	Yes	7	2	9	
Enterocutaneous Fistula	No	40	44	84	0.6
	Yes	2	1	3	

Table 6: operative time

	Type		P value
	Early Group	Late Group	
Operative time: Range	52-90 min.	50-71 min.	0.69
Mean	68.05 +/- 10.7	Mean 59 +/- 6.9	

Table 7: (Quality of life)

Time	Type		P value
	Early Group	Late Group	
At 2 months			0.25
Range	80 – 112	75 - 105	
Mean	Mean 98.7 +/- 11.2	Mean 93 +/- 10.2	
At 6 months			0,12
Range	94 - 118	83 - 106	
Mean	Mean 102 +/- 8.2	Mean 95 +/- 6	

At 12 months Range Mean	95 - 117 Mean 106 +/- 11	89 - 112 Mean 104 +/- 8	0.8
-------------------------------	-----------------------------	----------------------------	-----

Discussion

Defunctioning loop ileostomy is usually performed to protect low extraperitoneal or risky colorectal anastomosis "or coloanal anastomosis, and to alleviate the consequences of anastomotic Leakage, such as fecal fistula, intraperitoneal sepsis and reoperation [11].

As routine practice, ileostomy was closed 8-12 months after index operation to allow recovery after surgery, adequate healing of colorectal anastomosis, and both reduction of inflammation and adhesions around the stoma, to decrease the operative difficulty associated with ileostomy closure [13].

The feasibility of early ileostomy closure (within 2-3 weeks of the index operation) has been reported by several pilot studies with promising results [14-15].

Although, reversal of covering ileostomy is considered a simple operation, it has its own morbidity as anastomotic dehiscence, intestinal obstruction and wound infection.

In 3-25% of diversion temporary ileostomies may not be reversed. And become permanent and more will be delayed due to prolonged recovery from index surgery, post-operative complications, surgical site infection, and adjuvant chemotherapy treatment. [16]

The safety, efficacy, and feasibility of early closure of a temporary ileostomy in patients with rectal cancer were evaluated in this randomized clinical study done on 100 patients in our hospital.

The non-reversal rate in this study was 13%, (8pts. from early group and 5 pts. from late group), and this is much lower than reported by **Afroz Khan F. Airani et.al** who reported 23,36% non-reversal rate [17], and higher than 9,1% reported by Sier et.al [18].

The most important strength aspect in this study is, it contained homogeneous group of patients having the same diagnosis of rectal carcinoma,

and had almost the same surgical management.

Most of them were male, complaining of lower or mid rectal cancer, down staged by neo adjuvant radiotherapy and surgically treated by open low anterior resection with diverting loop ileostomy, and this is in contrary with many studies as A. Alves et.al and Nadeem Ali Shah et.al which include patients with various (benign or malignant) indications of ileostomy [9,13].

There is no significant difference between both groups as regards patients' demographics and the characteristics of the tumors resected.

In spite of its protective importance, diverting loop ileostomy has many adverse effects such as, dermatitis, parastomal infection, electrolyte imbalance, dehydration from high stoma output, renal insufficiency, stenosis, retraction, necrosis, prolapse and stricture that may necessitate re-admission and reoperation. It has also many adverse psychological morbidities leading to an adverse effect on the quality of life [12].

In this study, stoma-related complication occurred in 32 patients in late group and in 9 patients in early group, and from these morbidities, skin maceration and dehydration were significantly higher in late group.

Ileostomy closure is a simple procedure with a relatively low rate of complications, including postoperative ileus, adhesive intestinal obstruction, anastomotic leakage, surgical site infection, and incisional hernia [19].

Post closure complications occurred in 9 patients in early group, and in 3 patients in late group, but most of these were surgical site infections which, managed conservatively.

These results are consistent with the results obtained by **Taha Mohamed Fayed, et al, where they found that** patients in the early group (20 pts.) had fewer complications than patients in the late group (20 pts) during the follow up period [20], and the results of Alves. A

et al, where patients had an overall morbidity of 31% in the early closure group and 38% in the late closure group at 90 days after stoma creation^[13].

Also, these results cope with the results of a prospective pilot study done by Bakx R and colleagues, that showed that earlier reversal (median 11 days instead of 2 or 3 months) was not associated with increased morbidity or mortality^[15].

However, few studies contradict these results and do not recommend early closure of loop ileostomy like that done by Bausys A. et al that found that the overall 30 days postoperative morbidity rate was significantly higher in the early group (27.9% vs 7.9%) in the late group^[21].

The mean operative time in early group (68 min.) was found slightly longer than late group (59 min.), and this could be explained by some edema and inflammation encountered in the early group during closure, and this is matching with the results obtained by Alves. A et al^[13]. And some researchers even report shorter time than those during late group, indicating no additional technical difficulties^[22-24].

The second endpoint in this study is measurement of health-related quality of life between the studied patients, and this was measured in this study by using the Gastrointestinal Quality of Life Index {GIQLI}^[10] 2,6 and at 12 months after the index operation.

At all these scheduled times, the score of {GIQLI} in the early group was higher than that of late group, but this did not reach significant difference, This is consistent with the results of Alves. A et al who stated that, quality of life at 12 months were similar in both groups by using the same index^[13], and contradict with the results of Danielsen AK et al and OLeary DP et al who found that, a low anterior resection of the rectum with routine temporary loop ileostomy produced a marked impairment in health-related quality of life after construction, and improved significantly after ileostomy closure^[25,26].

Although, cost effectiveness did not included as an endpoint in this study, early closure could

save costs of multiple hospital admissions due to the stoma related complications and reduce the financial burden on the patients (by purchasing multiple appliances and collecting bags) specially in developing countries like Egypt.

Conclusion

Early closure of defunctioning loop ileostomy after low anterior resection for rectal cancer is feasible and safe in selected patients (fit and have normal distal loop studies).

It has also a positive impact on the quality of life of these patients, and saved them from many serious stoma related complications.

Declarations

Conflict of interest: The authors declare that there is no conflict of interests.

Ethical approval: Ethical approval was granted for the study by Menoufia University-Faculty of Medicine's ethics committee according to the Declaration of Helsinki. It was taken for research done on patients diagnosed with cancer breast.

References

- [1] 1-American Cancer Society. Cancer facts and figures 2014. <http://www.cancer.org/acs/groups/content/@research/documents/>
- [2] Ibrahim AS, Khaled HM, Mikhail NN, Baraka H, Kamel H. Cancer incidence in Egypt: results of the national population-based cancer registry program. *J Cancer Epidemiol.* 2014;2014:437971. [webcontent/acspc-042151.pdf](http://www.webcontent/acspc-042151.pdf). Accessed January 20, 2017.
- [3] Gessler B, Haglind E, Angenete E. Loop ileostomies in colorectal cancer patients morbidity and risk factors for nonreversal. *J Surg Res.* 2012;178(2):708-14.
- [4] Chadi SA, Fingerhut A, Berho M, et al. Emerging trends in the etiology, prevention, and treatment of gastrointestinal anastomotic leakage. *J Gastrointest Surg.* 2016;20:2035-2051.
- [5] Vallance A, Wexner S, Berho M, et al. A collaborative review of the current concepts and challenges of anastomotic leaks in colorectal surgery. *Colorectal Dis.* 2017;19:O1-O12. doi: 10.1111/codi.13534.
- [6] Montedori A, Cirocchi G-R, Farinella E, et al. Covering ileo- or colostomy in anterior resection for rectal carcinoma. *Cochrane Database Syst Rev.* 2010;(5):CD006878.
- [7] Matthiesen P, Hallboöck O, Rutegaard J, et al.

- Defunctioning stoma reduces symptomatic anastomotic leakage after low anterior resection of the rectum for cancer. *Ann Surg.* 2007; 246:207e14.
- [8] Pommergaard H-, Gessler B, Burcharth J, Angenete E, Haglind E, Rosenberg J. Preoperative risk factors for anastomotic leakage after resection for colorectal cancer: a systematic review and meta-analysis. *Colorectal Dis.* 2014;16(9):662-71.
- [9] Shah NA, Hussain M, Kalim M, Mehreen T, Shah I, Abid J. Experience with early versus routine enteric stoma closures: A comparative study. *J Postgrad Med Inst.* 2016;30(4):360-3.
- [10] Eypasch E, Williams JI, Wood-Dauphinee S, Ure BM, Schmulling C, Neugebauer E et al. Gastrointestinal Quality of Life Index: development, validation and application of a new instrument. *Br J Surg.* 1995;82:216–222.
- [11] Marusch F, Koch A, Schmidt U et al. Value of a protective stoma in low anterior resections for rectal cancer. *Dis Colon Rectum.* 2002;45:1164–1171.
- [12] O’Toole GC, Hyland JM, Grant DC et al. Defunctioning loop ileostomy: a prospective audit. *J Am Coll Surg.* 1999;188:6–9.
- [13] Alves A, Panis Y, Lelong B et al. Randomized clinical trial of early versus delayed temporary stoma closure after proctectomy. *Br J Surg.* 2008;95:693–698.
- [14] Velmahos GC, Degiannis E, Wells M et al. Early closure of colostomies in trauma patients—a prospective randomized trial. *Surgery.* 1995;118: 620–815
- [15] Bakx R, Busch ORC, van Geldere D et al. Feasibility of early closure of loop ileostomies. *Dis Colon Rectum.* 2003;46:1680–1684
- [16] Worni M, Witschi A, Gloor B, Candinas D, Laffer UT, Kuehni CE. Early closure of ileostomy is associated with less postoperative nausea and vomiting. *Dig Surg.* 2011;28(5-6):417-23.
- [17] Afroz Khan F, Airani*, Chitra Y, Bhat, Bharat S. V., Gabriel Rodrigues. How temporary is temporary ileostomy: variables delaying reversal of an ileostomy, *Int Surg J.* 2019;6(1):66-72
- [18] Sier MF, van Gelder L, Ubbink DT, Bemelman WA, Oostenbroek RJ. Factors affecting timing of closure and non-reversal of temporary ileostomies. *Int J Colorectal Dis.* 2015;30(9): 1185-92.
- [19] Robertson I, Eung E, Hughes D, Spires M, Donnelly L, Mackenzie I, et al. Prospective analysis of stoma related complications. *Colorectal Dis.* 2005;7: 279–85.
- [20] Taha Mohamed Fayed, Ayman Mohammed AbdulMohaymen, and Eid Rizk El Gammal. Early Versus Delayed Reversal of Covering Stoma after Low Anterior Resection for Colorectal Carcinoma, *The EGYPTIAN JOURNAL OF HOSPITAL MEDICINE.* 6920-6915 Page (6), 73 Vol.
- [21] Bausys A, Kuliavas J, Dulskas A, et al. Early versus standard closure of temporary ileostomy in patients with rectal cancer: A randomized controlled trial. *J Surg Oncol.* 2019;1-6.
- [22] Krand O, Yalti T, Berber I et al. Early vs delayed closure of temporary covering ileostomy: a prospective study. *Hepatogastroenterology.* 2008; 55:142–145.
- [23] Danielsen AK, Park J, Jansen JE et al. Early closure of a temporary ileostomy in patients with rectal cancer: a multicenter randomized controlled trial. *Ann Surg.* 2017;265:284–290.
- [24] Lasithiotakis K, Aghahoseini A, Alexander D (2016) Is early reversal of defunctioning ileostomy a shorter, easier and less expensive operation? *World J Surg* 40:1737–1740. <https://doi.org/10.1007/s00268-016-3448-7>
- [25] Anne Kjaergaard Danielsen, Adiola Correa-Marinez, Eva Angenete, Stefan Skullmann, Eva Haglind, Jacob Rosenberg, SSORG (Scandinavian Outcomes Research Group). Early closure of temporary ileostomy the EASY trial: protocol for a randomised controlled trial, *BMJ Open* (2011). doi:10.1136/bmjopen-2011-000162 5.
- [26] O_Leary DP, Fide CJ, Foy C, et al. Quality of life after low anterior resection with total mesorectal excision and temporary loop ileostomy for rectal carcinoma. *Br J Surg.* 2001;88:1220.

